

Histopathological Study of Colorectal Malignancy—A Five Year Experience

*Dr N Rajesh Kumar M.D., **Dr Komala.H.M.M.D.,

*Associate Professor, Department Of Pathology, Annapoorna Medical College And Hospital, NH 47, Sankari Road, Serangapadi, Salem, India.

**Assistant Professor, Department Of Pathology, Annapoorna Medical College And Hospital, NH 47, Sankari Road, Serangapadi, Salem, India.

Objectives: The aim of the study is to determine the histopathological features of primary colorectal cancers.

Materials and methods: 102 patients with primary colorectal tumors diagnosed over a 5 year period studied histopathologically they were classified using the WHO classification of colorectal malignancies. primary gastrointestinal tumors

Diagnosis. Result: Most of the colorectal tumors were adenocarcinoma 85% and most were tubular carcinoma and other were papillary and mucinous adenocarcinoma. Though the squamous cell carcinoma remains the second common tumor and comprising about only 6.5 % of all the total malignant neoplasm, and carcinoid, GIST, melanoma, Non Hodgkin's lymphoma, poorly differentiated carcinoma comprising about 1 % of the colorectal cancers.

Conclusion: Most of the colorectal tumors were adenocarcinoma 85% arising from the proximal colon and in the sigmoid rectum, most were tubular carcinoma and other were papillary and mucinous adenocarcinoma. Squamous cell carcinoma remains the second common tumor and comprising about only 6.5 % and occurring in the anorectal region as well as malignant melanoma common in the anal canal and in the anus. The other tumors carcinoid, GIST, melanoma, Non Hodgkin's lymphoma, poorly differentiated carcinoma comprising about 1 % of the colorectal cancers and scattered through out the large bowel.

Keywords: Primary large bowel malignancy, colorectal carcinomas.

I. Introduction

The incidence of carcinoma is 36 times greater in the colon than in the small bowel. Malignant tumors of the small intestine are associated with Crohn's disease, villous adenoma and adult celiac disease¹. Small bowel lymphoma and adenocarcinoma are the other recognized complications of celiac disease².

Virtually 98% of all cancers in the large intestine are adenocarcinomas. They represent one of the prime challenges to the medical profession, because they usually arise in polyps and produce symptoms relatively early and at a stage generally curable by resection. Yet, there are an estimated 148,300 new cases per year and about 56,600 deaths, accounting for 10% of all cancer-related deaths in the United States⁴. The peak incidence for colorectal carcinoma is between ages 60 and 79. Fewer than 20% of cases occur before age 50. Colorectal carcinomas in young persons are usually associated with ulcerative colitis or one of the polyposis syndromes. The incidence of synchronous and metachronous colorectal carcinoma in 223 patients with colorectal carcinoma, 24 patients had multiple colorectal carcinomas, 18 were synchronous and 6 cases were metachronous³.

Adenosquamous carcinomas which constitutes 5 % of all malignant tumors of colon, with a median age of 52 years and male to female ratio 1.4:1 and commonly located in sigmoid colon⁴.

colorectal carcinoma which constituted 17.2% when compared to advanced colorectal carcinoma; further his study showed that 82% were adenoma carcinoma sequence⁵.

small cell carcinomas of the large intestine, most were located on the right colon, endocrine differentiation was present in all tumors; these were aggressive tumors with a propensity for early liver involvement⁶.

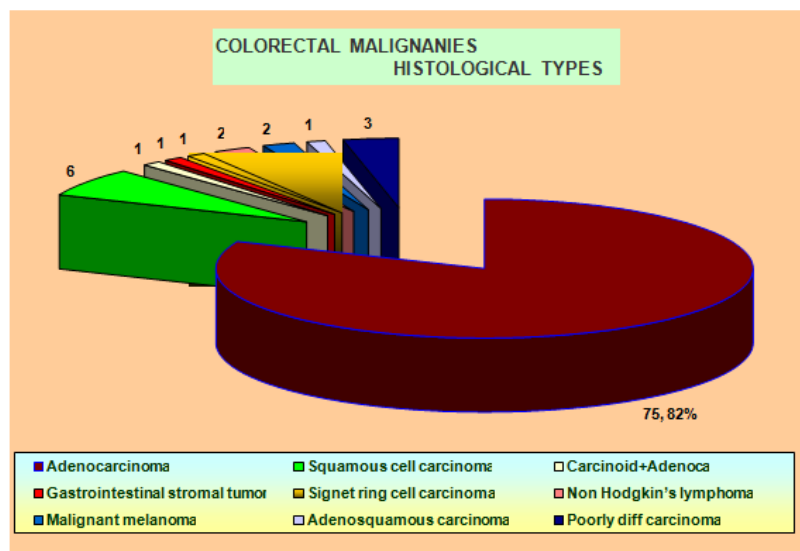
II. Material and Methods

Primary colorectal carcinomas 95 cases, diagnosed at Tertiary Care Hospital in Tamil Nadu, India over a period of 5 years (2011-2016) were studied. The laboratory and radiological work- up done. The histological pattern and the histological types of tumors were analyzed under Hamatoxylin and Eosin stain and computed tomography (CT), magnetic resonance imaging (MRI) and endoscopy findings were collected. The immunohistochemical profile and special stains was performed were ever indicated.

III. Observation

Table 1: Incidence and sex wise distribution of various histological types of large intestine malignancies.

Histological type	Total cases	Males	Females	M:F
Adenocarcinoma	75(81.5%)	47(62.6%)	28(37.4%)	1.67:1
Squamous cell carcinoma	6(6.52%)	3(50%)	3(50%)	1:1
Carcinoid Adenocarcinoma	1(1.08%)	-	1	0:1
GIST	1(1.08%)	-	1	0:1
Signet ring cell carcinoma	1(1.08%)	1	-	1:0
Non Hodgkin's lymphoma	2(2.16%)	2	-	2:0
Malignant melanoma	2(2.16%)	2	-	2:0
Adenosquamous Carcinoma	1(1.08%)	1	-	1:0
Poorly differentiated Carcinoma	3(3.34%)	-	3	0:3



IV. Discussion

Virtually, 98% of all cancers in the large intestine are adenocarcinomas⁷. They represent one of the prime challenges to the medical profession, because they usually arise in polyps and produce symptoms relatively early and at a stage generally curable by resection. Yet, there are an estimated 148,300 new cases per year and about 56,600 deaths, accounting for 10% of all cancer-related deaths in the United States⁸.

The peak incidence for colorectal carcinoma is between ages 60 and 79. Fewer than 20% of cases occur before age 50. When colorectal carcinoma is found in a young person, pre-existing ulcerative colitis or one of the polyposis syndromes must be suspected. With lesions in the rectum, the male-to-female ratio is 1.2:1; for more proximal tumors there is no gender difference⁹. Colorectal carcinoma has a worldwide distribution, with the highest death rates in the United States, Australia, New Zealand, and Eastern European countries. Its incidence is substantially lower-up to 10-fold-in Mexico, South America, and Africa. Environmental factors, particularly dietary practices, are implicated in these striking geographic contrasts in incidence. Japanese and Polish families that have migrated from their low-risk areas to the United States have acquired, over the course of 20 years, the rate prevailing in the new environment. Both groups, for the most part, adopted the common dietary practices of the U.S. population. Other studies implicate obesity and physical inactivity as risk factors for colon cancer.

Adenocarcinoma can be divided into three grades based primarily on an overview of the arrangement of cells with regard to the degree of tubular (acinar) formation. 15% to 20% of colorectal adenocarcinomas are grade I (low-grade or well-differentiated tumors), 60% to 70% are grade II (moderately differentiated tumors), and 15% to 20% are grade III (poorly differentiated tumors)¹⁰. Grade I cancers are composed mainly of simple tubules, in which the nuclear polarity is easily discerned and the nuclei are of uniform size. Grade II cancers are composed of tubules that may be simple, complex, or slightly irregular, in which the nuclear polarity is barely discernible or is lost. Grade III tumors are characterized by a predominance of the absence of glandular differentiation (solid-like pattern), as well as by loss of nuclear polarity. Grade III cancers have a significantly poorer prognosis than grade I and II lesions. To define a colorectal carcinoma as a grade III lesion, the poorly differentiated component should form more than 50% of the tumor rather than representing only small rare foci of the neoplasm.

Small cell cancer is a rare variant which comprises less than 1% of colorectal cancers. Histologically, these cancers are identical to small cell carcinoma of the lung (oat cell type and intermediate type)¹¹. They have an extremely poor prognosis, and almost all cases have lymphnode and liver metastasis.

Rectal carcinoids that are larger than 2 cm and or that display invasion of the muscularispropria and or that have two or more mitosis per 10 high-power fields have the potential to metastasize, and these should be considered malignant lesions¹². Tumors smaller than 2 cm but with invasion of blood vessels, lymphatics, nerves, muscularispropria, anaplasia and increased mitoses may also behave as malignantly. Lesions without any of the foregoing features should be considered benign, and they may be effectively cleared by local excision.

V. Conclusion

Most of the colorectal tumors were adenocarcinoma 85% arising from the proximal colon and in the sigmoidectum, most were tubular carcinoma and other were papillary and mucinous adenocarcinoma. Squamous cell carcinoma remains the second common tumor and comprising about only 6.5 % and occurring in the anorectal region as well as malignant melanoma common in the anal canal and in the anus. The other tumors carcinoid, GIST, melanoma, Non Hodgins lymphoma, poorly differentiated carcinoma comprising about 1 % of the colorectal cancers and scattered throughout the large bowel.

Bibliography

- [1]. Vijay K Mittal, Jason H Bodzin; Primary malignant tumors of the small intestine. *The American journal of surgery* 140:396-399, 1980.
- [2]. P D Howdle, P K Jalal, G K T Holmes; Primary small bowel malignancy in the UK and its association with celiac disease. *Q J Med* 96:345-353, 2003.
- [3]. W J Cunliffe, P S Hasleton, D E F Tweedle et al; Incidence of synchronous and metachronous colorectal carcinoma. *British journal of surgery* 71:941-943, 1984.
- [4]. LizardoCerezo, Marcelino, Olga Edwards; Adenosquamous carcinoma of the colon. *Dis Colon &Rectum* 28:597-603, 1985.
- [5]. TadakazuShimoda, Masahiro, Junko et al; Early gastric carcinoma with special reference to its development de novo. *Cancer* 64:1138-1146, 1989.
- [6]. Allen B Burke, Kris M Shekitka, Leslie H Sobin; Small cell carcinoma of the large intestine. *Am J ClinPathol* 95: 315-321, 1991..
- [7]. National Cancer Registry Programme, consolidated report of hospital based cancer registries 2001-2003.125-126, 2007.
- [8]. J Milburn, Lamar, Glenn D Steele et al; The national cancer data base report on colon cancer. *Cancer* 78:918-926, 1996.
- [9]. J C Paymaster, L D Sanghvi, P Gangadharan; Caner in the gastrointestinal tract in Western India, epidemiologic study. *Cancer* 21:279-288, 1968.
- [10]. Denis P Burkkitt; Epidemiology of cancer of the colon and rectum. *Cancer* 28:3-13, 1971.
- [11]. Mark R Wick, R Paul, Louis H W; Small cell neuroendocrine carcinoma of the colon and rectum. *Human Pathology* 18:9-21, 1987.
- [12]. G R Williams, I C Talbot; Anal carcinoma- a histological review. *Histopathology* 25:507-516, 1994.